IMAGENS

MMC

OUVIDO

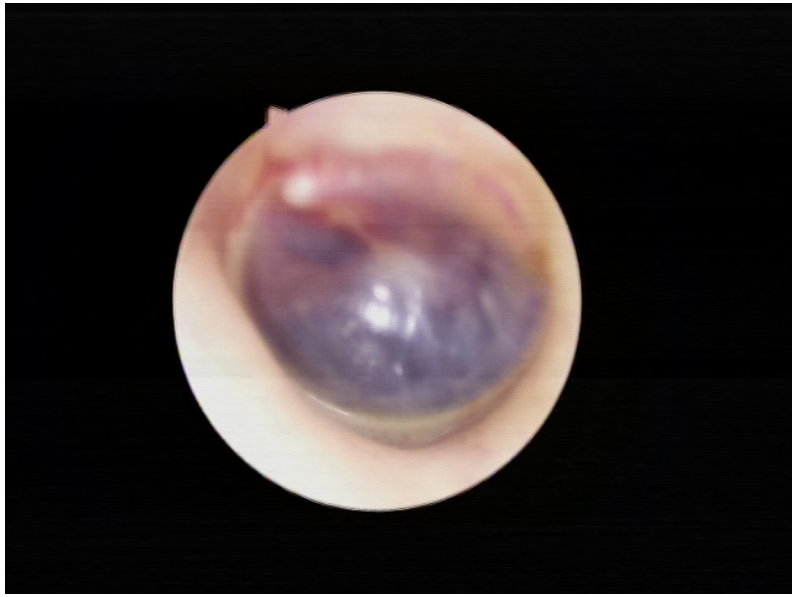

Hemotímpano

Pólipo da canal auditivo externo

OUVIDO

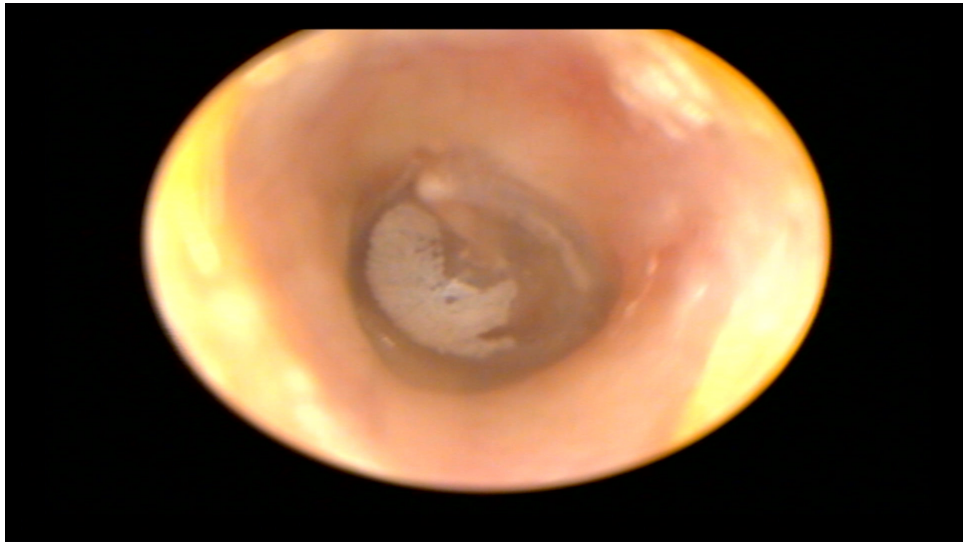

Timpanoesclerose

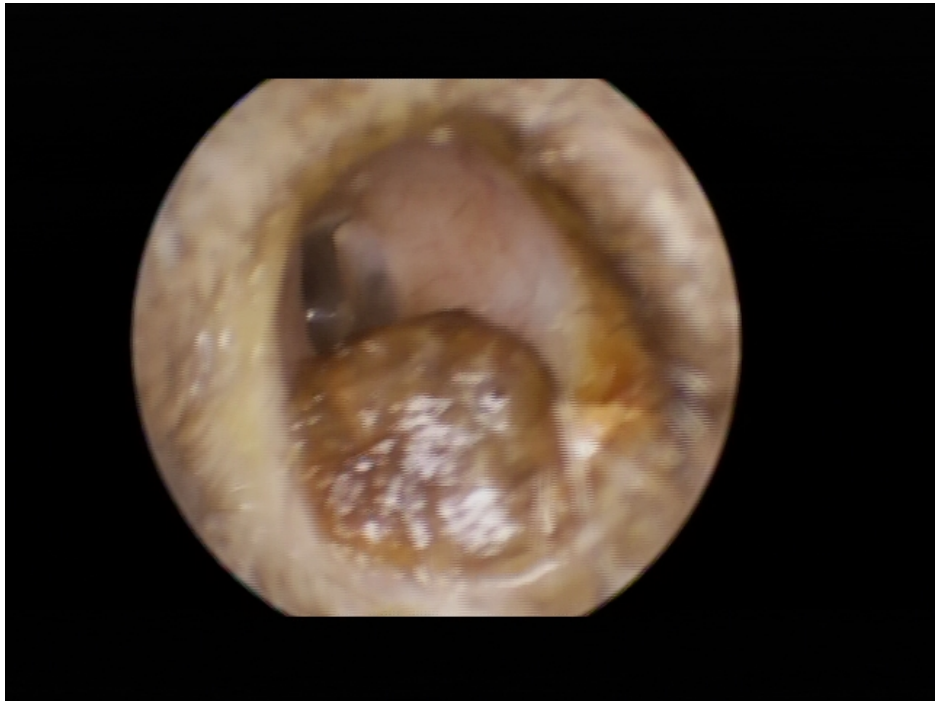

Cerumen do canal auditivo externo

OUVIDO

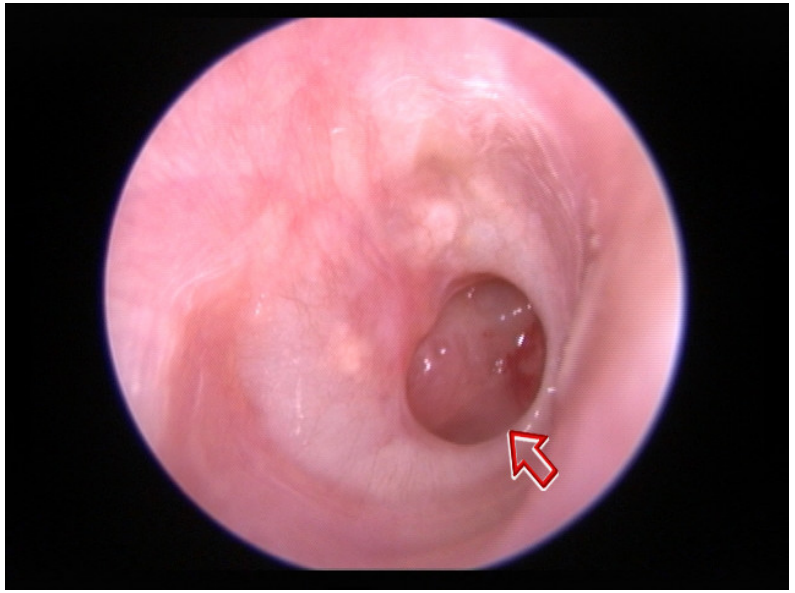

Perfuração da membrana timpanica

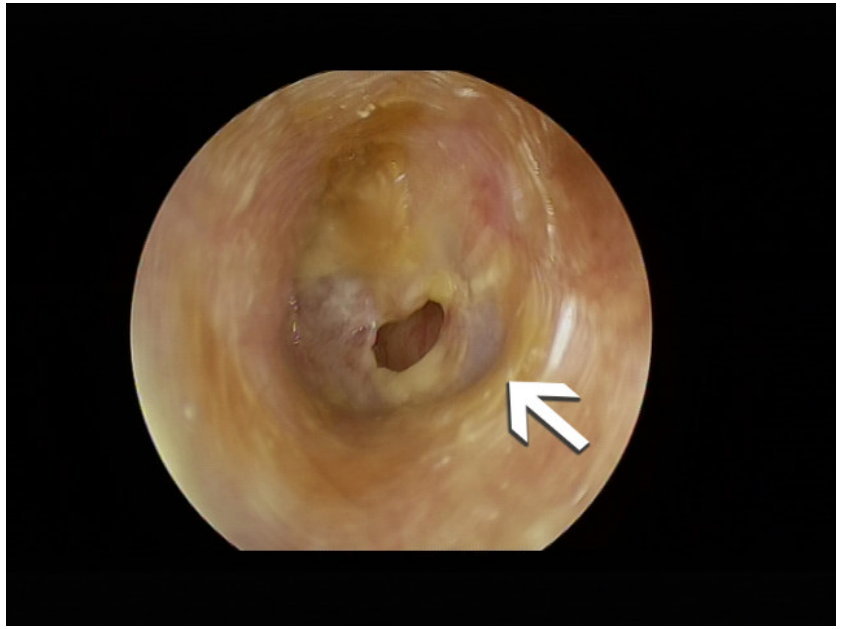

Perfuração da membrana timpanica

OUVIDO

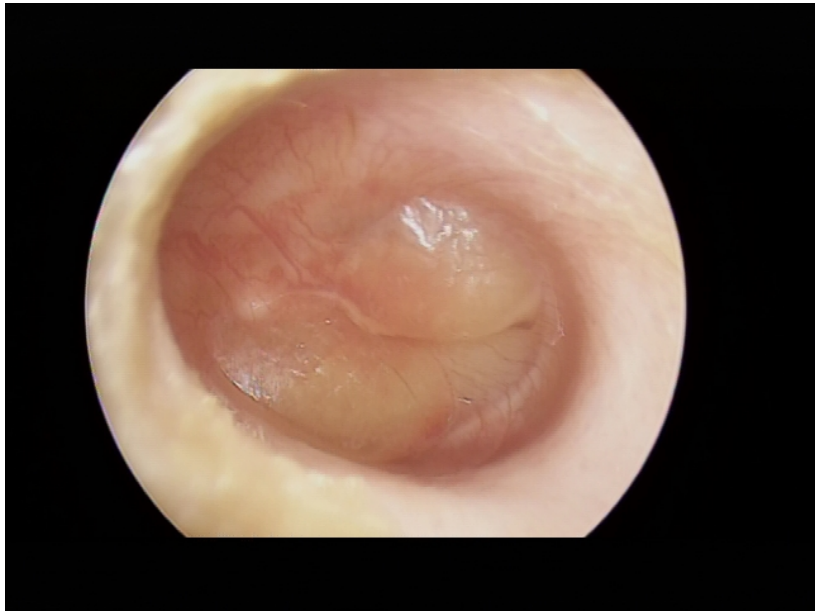

Otite media aguda

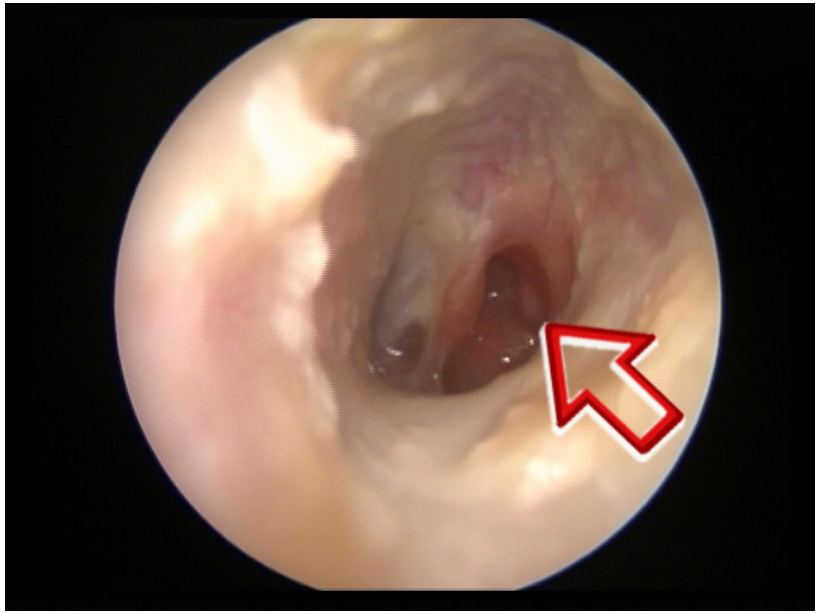

Otite media supurada

OUVIDO

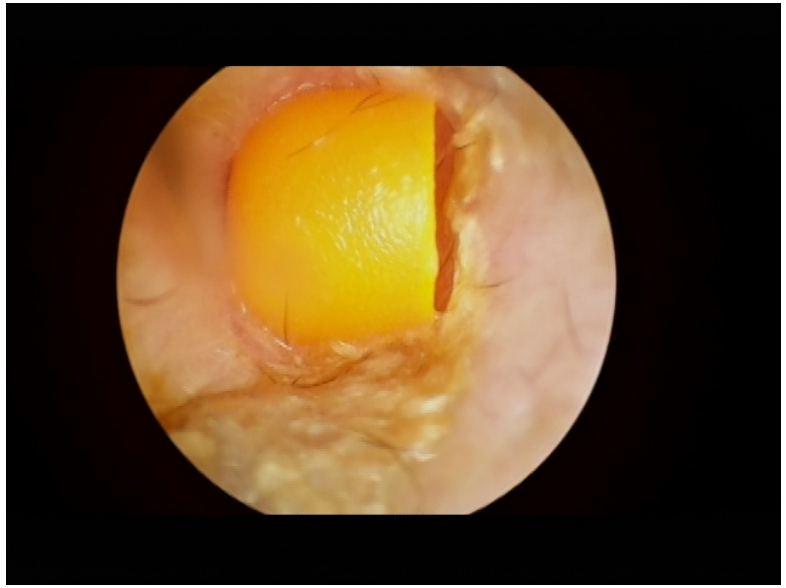

Corpo estranho no canal auditivo externo

Exostose do canal auditivo

OUVIDO

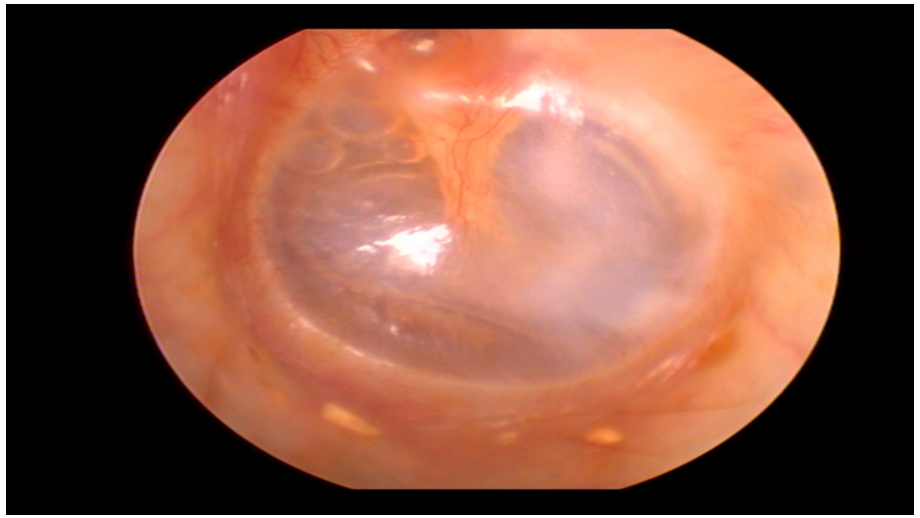

Otite media secretora

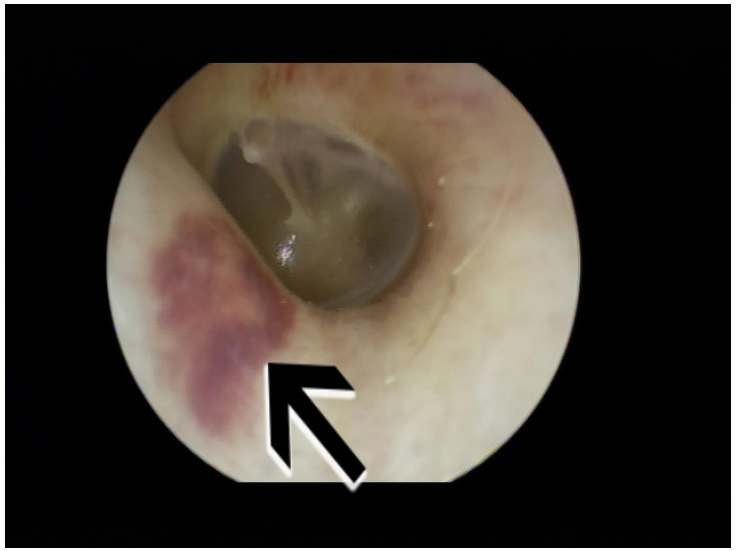

Trauma do canal auditivo externo

LARINGE

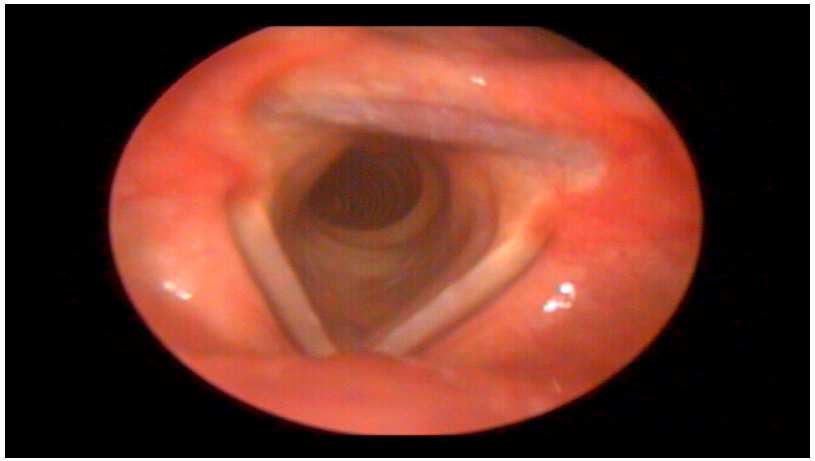

Laringe de um paciente com refluxo gastro-esofágico

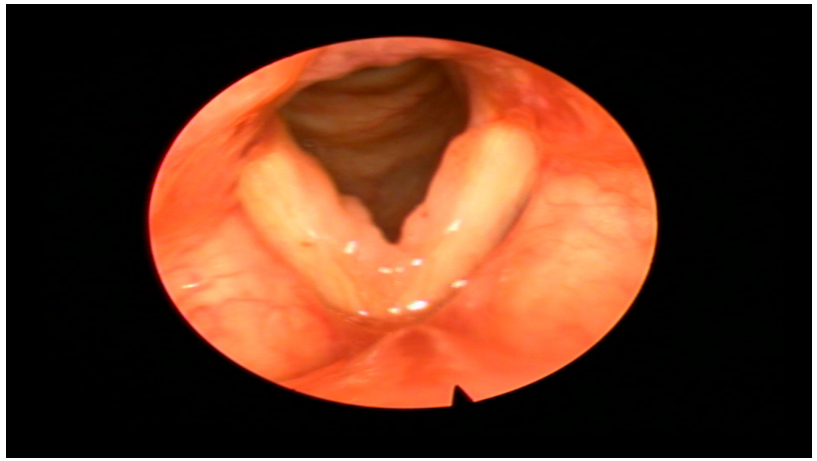

Papilomatose laringea

LARINGE

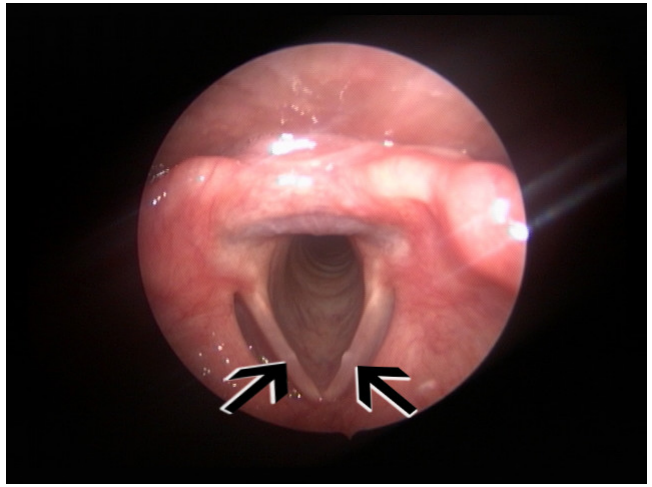

Micronodulos das cordas vocais

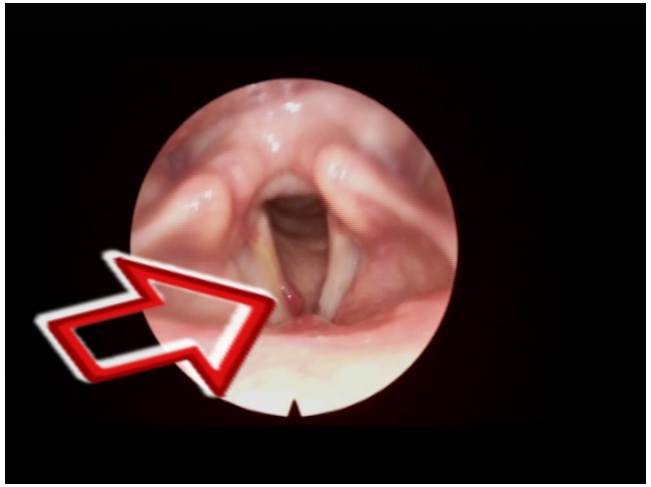

Hemangioma da corda vocal direita

LARINGE

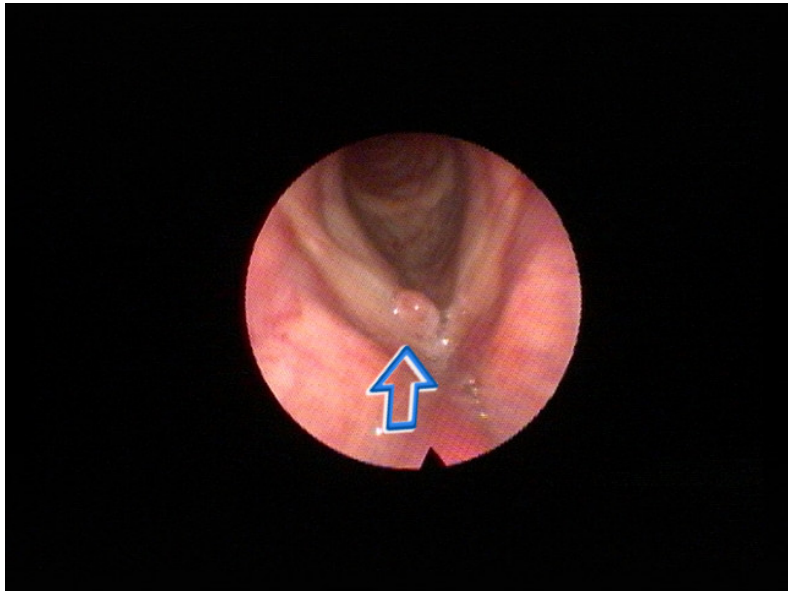

Polipo da corda vocal direita

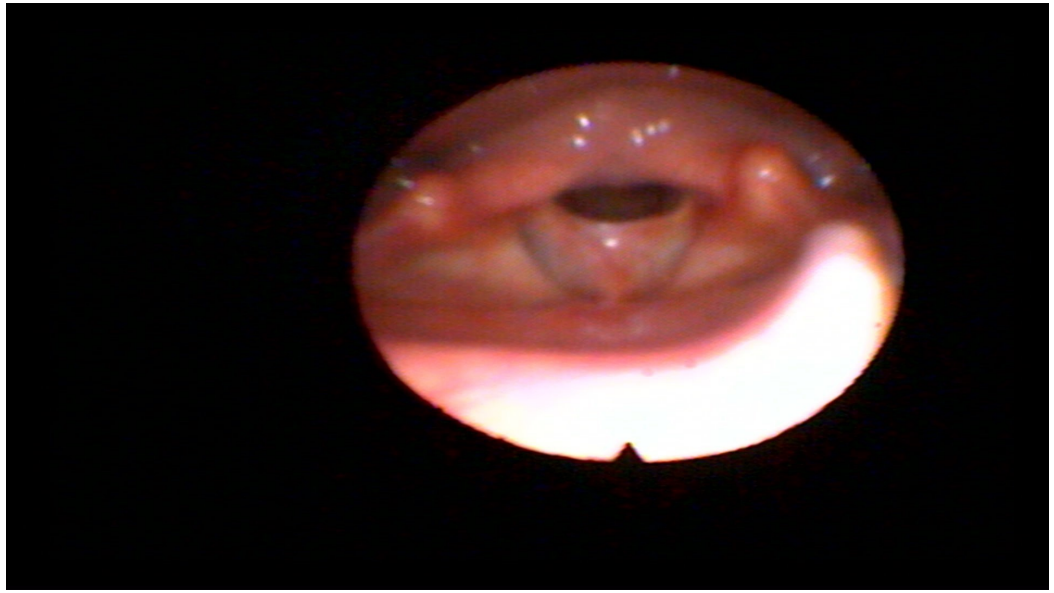

Sinêquia laríngea anterior

LARINGE

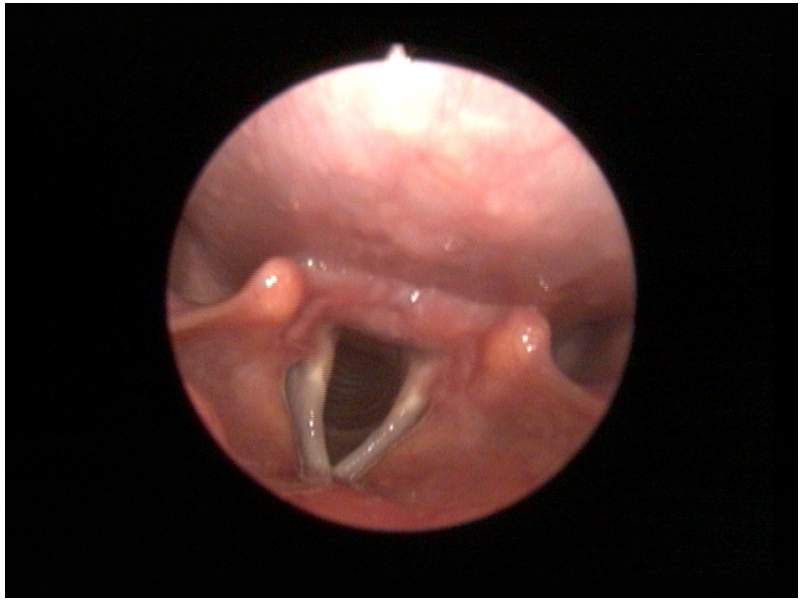

Laringe normal

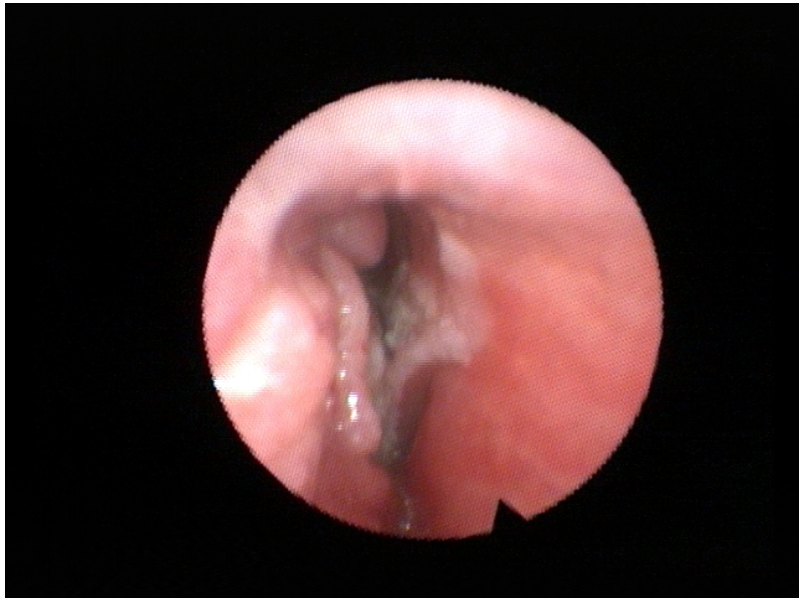

Carcinoma da laringe

NARIZ E SEIOS PERINASAIS

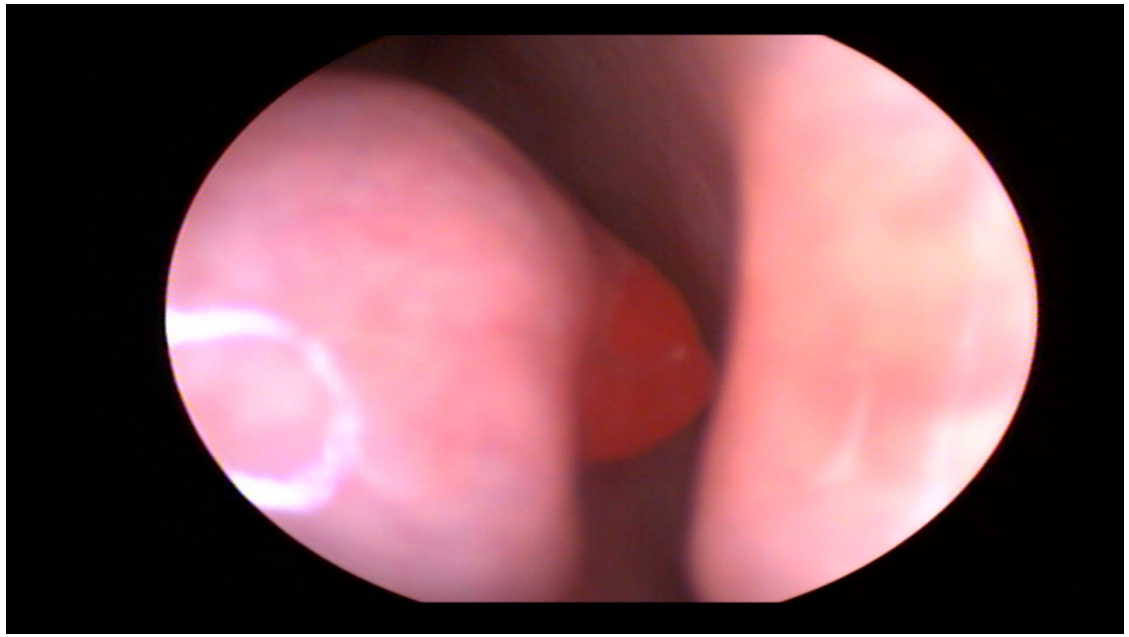

Hemangioma nasal

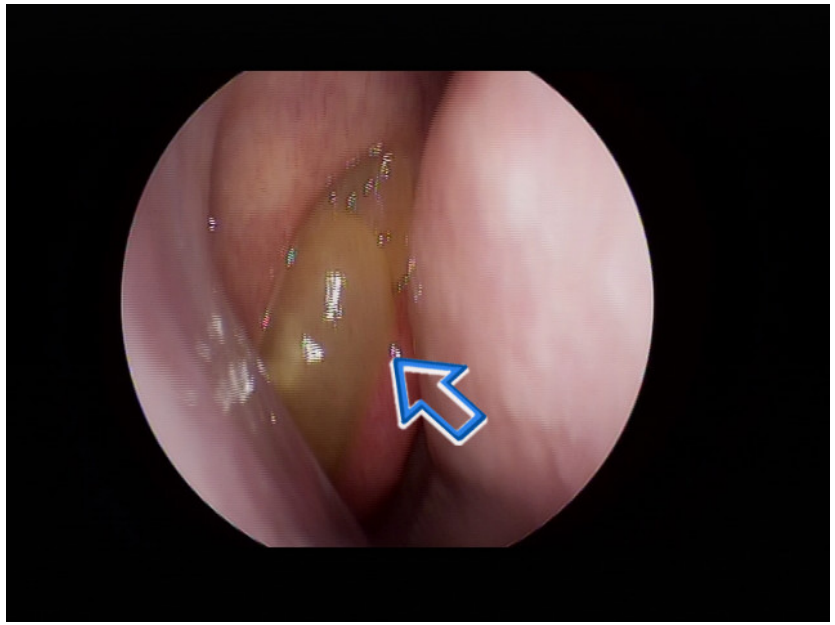

Pólipo nasal

NARIZ E SEIOS PERINASAIS

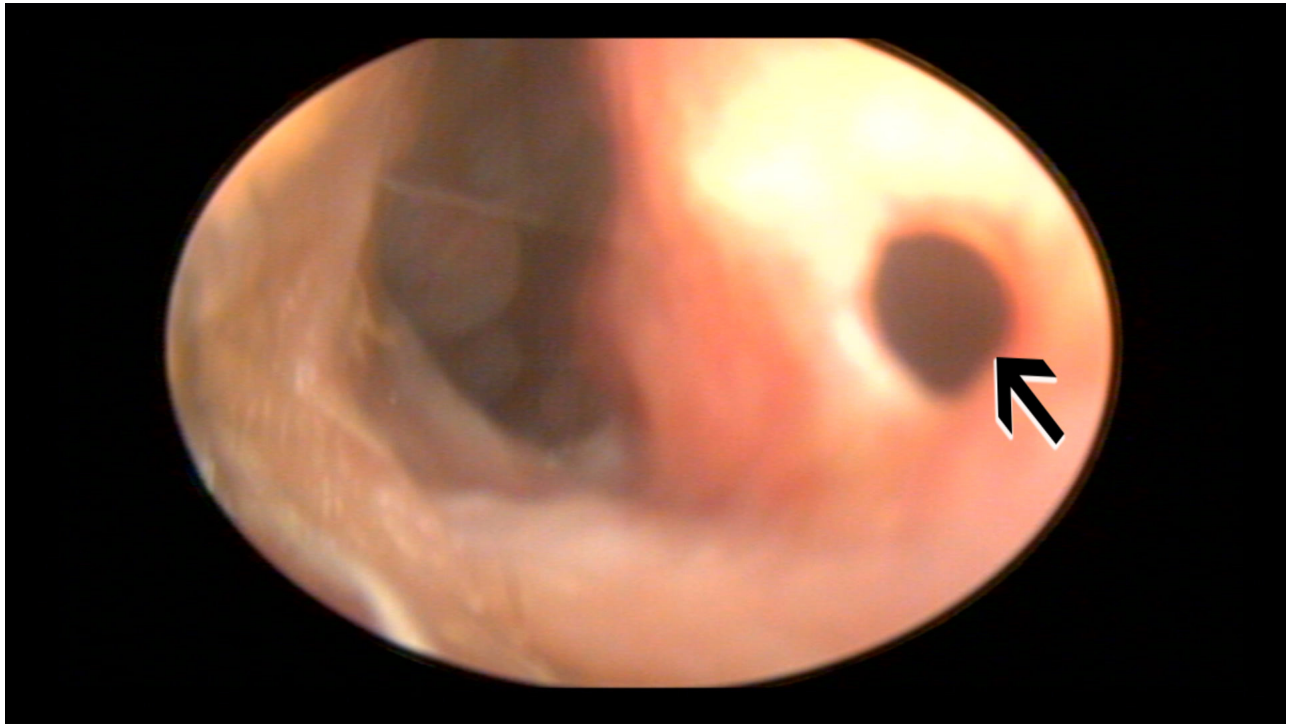

Perfuração septal

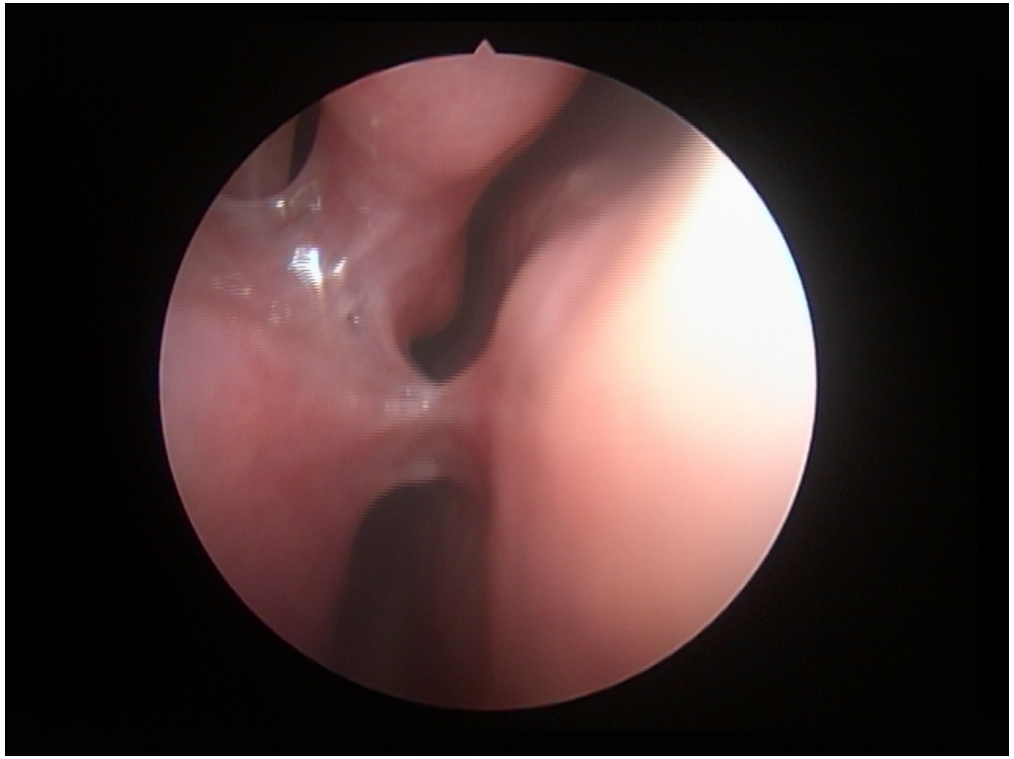

Sinêquias nasais

NARIZ E SEIOS PERINASAIS

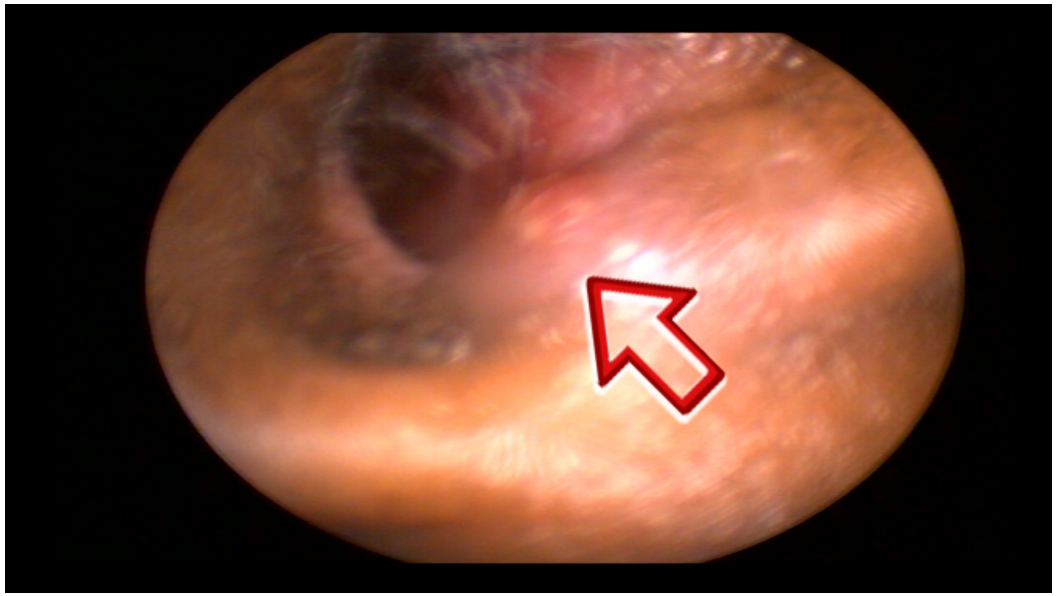

Furunculose nasal

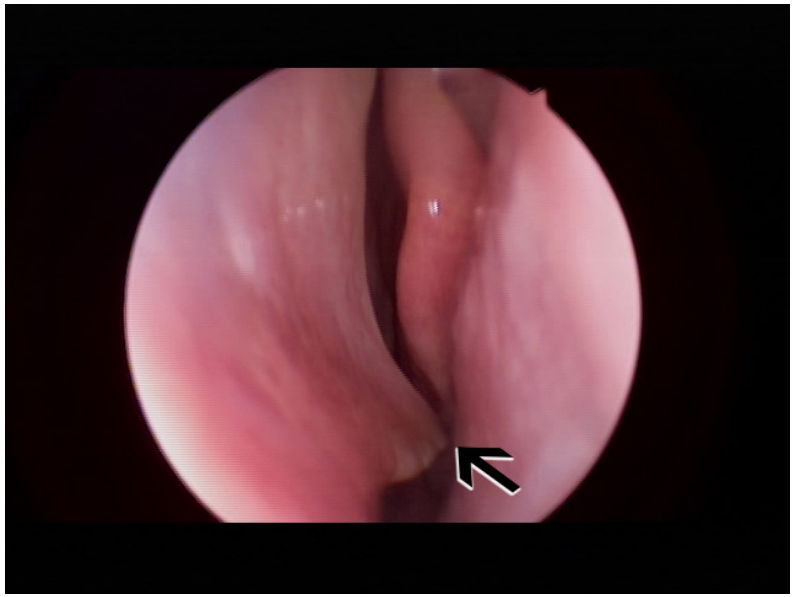

Esporão septal

OROFARINGE

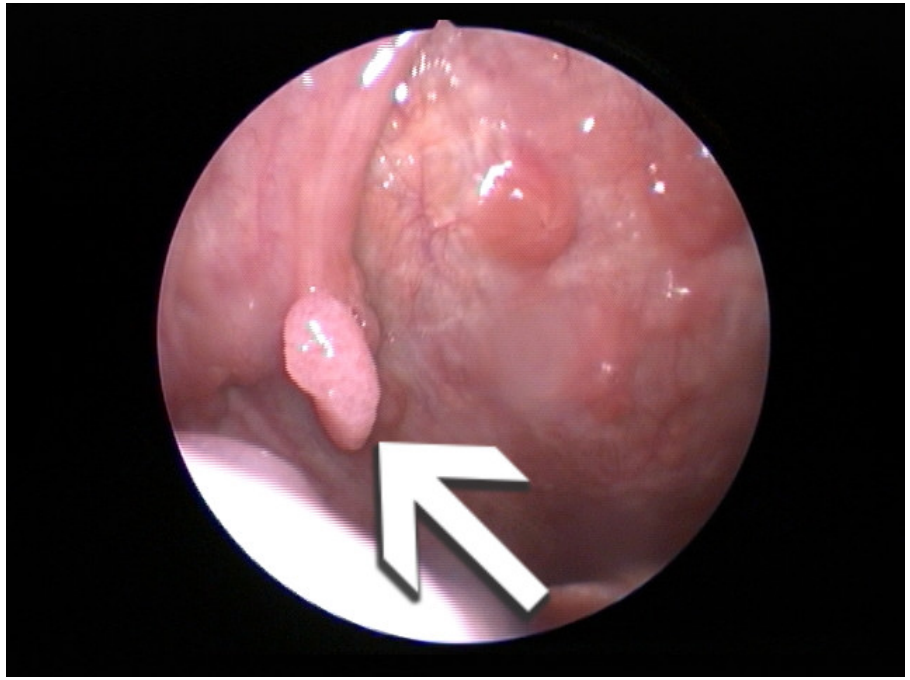

Papilomatose da orofaringe

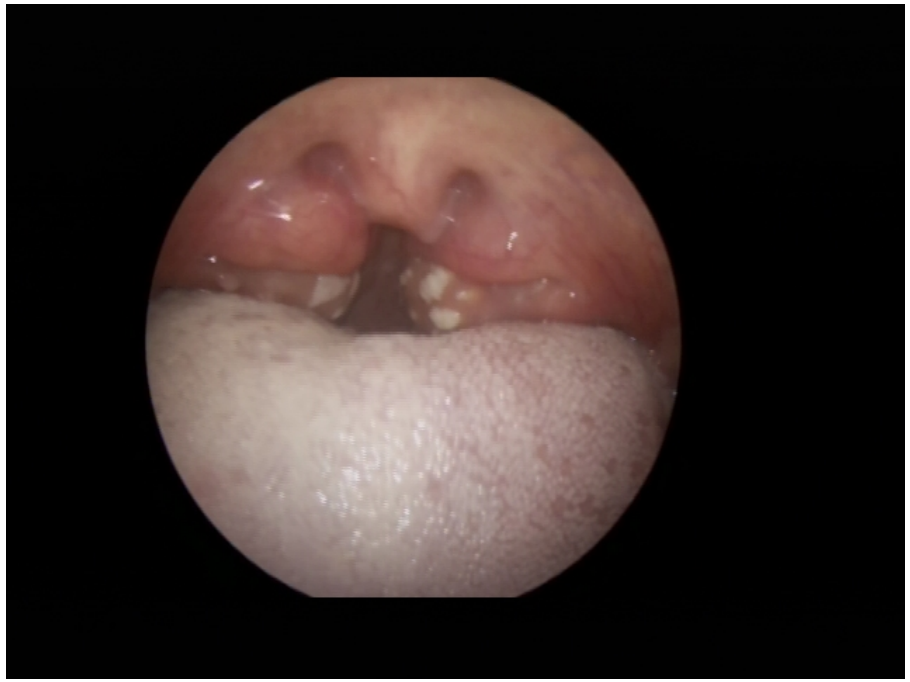

Amigdalite cronica agudizada
eritemo-pultacea

OROFARINGE

Pós operado- amigdalectomia (5º dia)

Pós operado- amigdalectomia (20º dia)

OROFARINGE

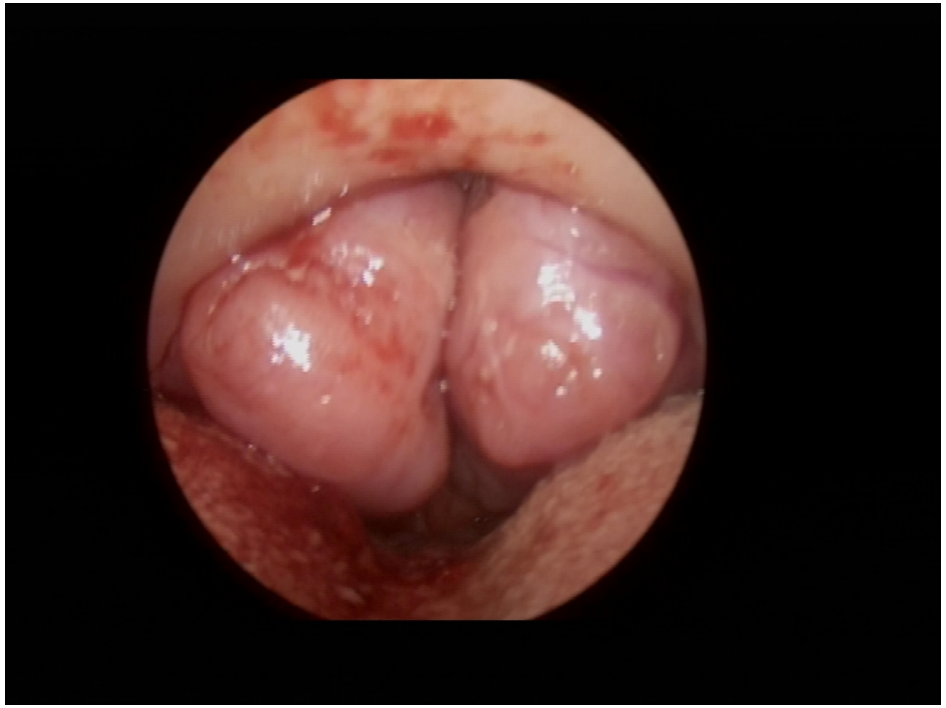

Hipertrofia amigdalina grau IV

Quisto amigdalino da amigdala esquerda

OROFARINGE

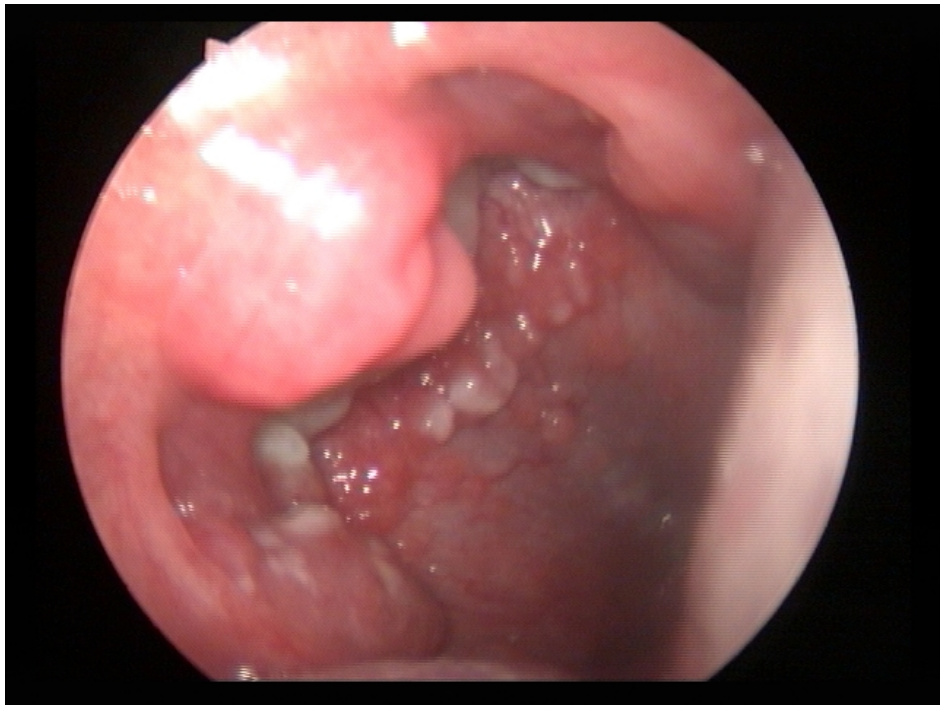

Hipertrofia adenoideia- fase aguda

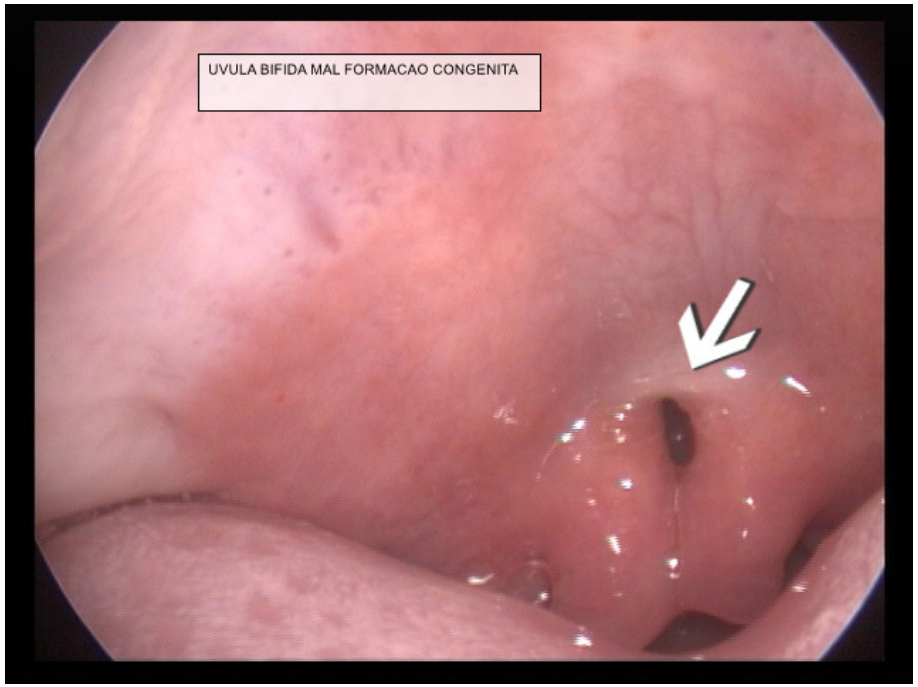

Úvula bífida